

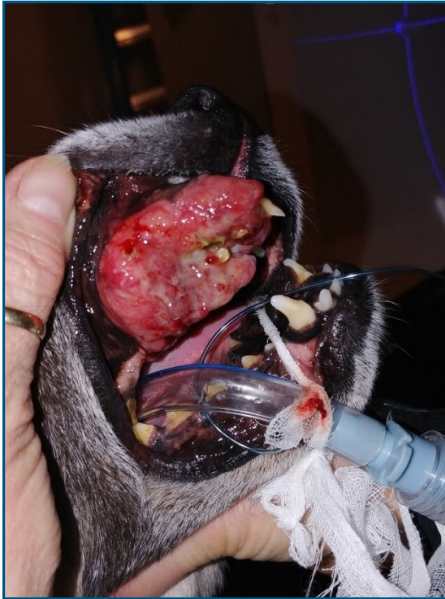

IMAGE A: Pre-Treatment  
3/26/2018

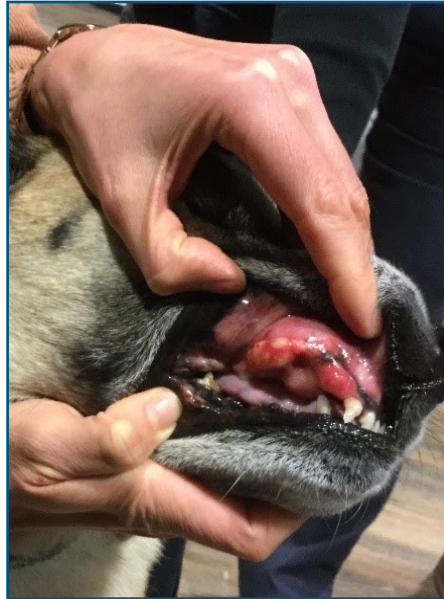


IMAGE B: 2 Weeks  
Post-Treatment  
4/19/2018

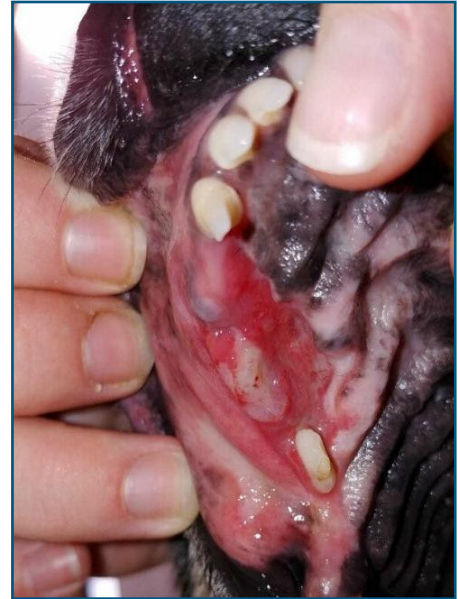

IMAGE C: 1 Month  
Post-Treatment  
5/3/2018

**PATIENT:** 11-year old, female, German Shepherd mix, neutered

**TUMOR HISTOLOGY:** Sarcoma

**ANATOMIC LOCALIZATION:** Maxillary

**BACKGROUND:** For this 11-year-old German Shepherd mix, treatment for a high-grade, rapidly growing maxillary sarcoma was critical. The pet owners were ready to act fast. Surgical removal was not recommended and would have required extensive reconstructive surgery. Stereotactic radiation (SRS/SRT) was recommended with excellent long-term prognosis if local control could be achieved.

**TREATMENT:** The pet owners elected SRS/SRT. She was treated with a single fraction at 20 Gy on April 5, 2018. Dr. Lauren Quarterman, radiation oncologist at PetCure Oncology at SAGE, managed her treatment.

**OUTCOME:** The patient did not experience any negative side effects from SRS/SRT and the patient continues to do well. The tumor has completely regressed and there is no evidence of gross residual disease at this time.

**RELEVANCE:** Oral tumors in dogs and cats are relatively common. According to the American College of Veterinary Surgeons (ACVS), "benign and malignant tumors of the oral cavity account for 3-12% of all tumors in cats and 6% of all tumors in dogs." This maxillary sarcoma was not a candidate for surgical removal and systemic treatment may have caused additional issues for the dog. Due to this rapid response, single-fraction treatments may be preferable to ensure precise delivery of high-dose radiation to the tumor before the target begins to shrink.

**IMAGE D: Approx. 2 Months  
Post-Treatment  
No Evidence of Cancer  
5/31/2018**

