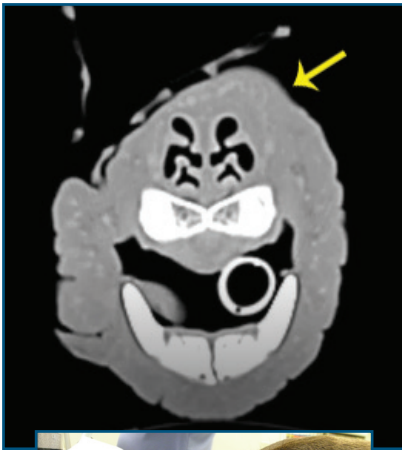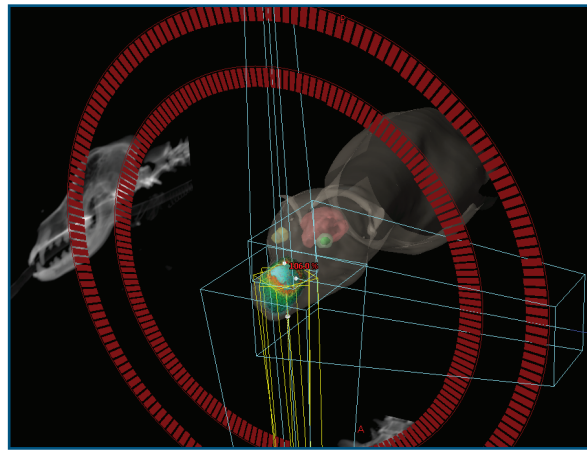
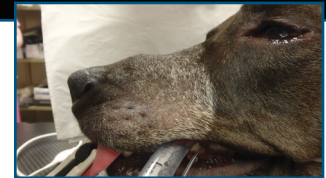





Pre-Treatment: 8/13/15



Above, Bindi's initial CT scan is used to create a volumetric 3D reconstruction of her tumor for treatment planning. The red dashed circles represent the paths of the arcs used to deliver the SRS. Normal critical structures can be visualized, such as the brain (pink), eyes, and lenses. The target volume (light blue/cyan) is also shown, encapsulated by the radiation dose cloud.



Post-Treatment: 11/10/15

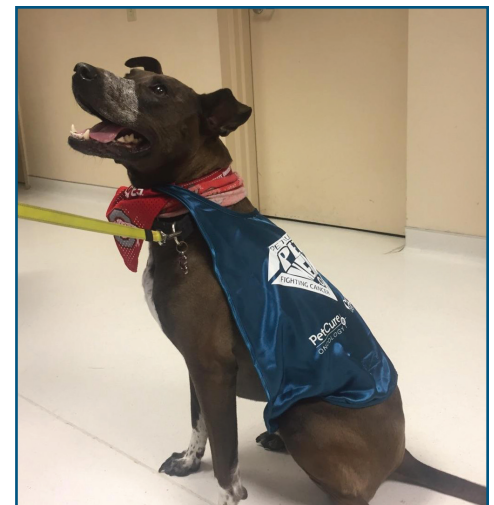**PATIENT:** Bindi, a 4-year-old, female, neutered mix

**TUMOR HISTOLOGY:** Mast Cell Tumor

**ANATOMIC LOCALIZATION:** Nose

**BACKGROUND:** Bindi presented with a large mast cell tumor (MCT) on the bridge of her nose. A CT scan revealed the mass to be deeply embedded and attached to underlying structures. As a result, complete surgical removal would have required extensive reconstructive surgery. MCT's are known to be radiation responsive. Stereotactic radiation (SRS/SRT) was recommended with excellent long-term prognosis (24+ months) if local control could be achieved.

**TREATMENT:** The pet owner elected SRS/SRT. Since MCT's often respond very rapidly to radiation, treatment was delivered in a single fraction of two arcs and 20 Gy on 8/14/15. Treatment plan resulted in good tumor dose homogeneity and completely spared both eyes.



Bindi, 18 months post-treatment

**OUTCOME:** Six- and 12-day follow-ups revealed visibly smaller tumor and no reported side effects. Three-month CT confirmed significant shrinkage and minimal swelling was visible. Bindi was determined to be in complete remission at that point. At the time of this case study, Bindi is alive and healthy 18 months post-treatment. Her only reported side effects were discoloration of fur over the treatment site and a discolored tooth.

**RELEVANCE:** MCT's are among the most common tumors found in dogs, accounting for 7% of cancer treated across PetCure Oncology's affiliated network. They are extremely radiation responsive and can shrink 50-75% within 12-24 hours of initial radiation dose. Due to this rapid response, single-fraction treatments may be preferable to ensure precise delivery of high-dose radiation to the tumor before the target begins to shrink.