

# Single high-dose radiation therapy and liquid fiducial markers can be used in dogs with incompletely resected soft tissue sarcomas

Timothy Ericksen, DVM<sup>1\*</sup>; Neal Mauldin, DVM, ACVIM, ACVR-RO<sup>2</sup>; Ryan Dickinson, DVM, ACVP<sup>3</sup>; Glenna Mauldin, DVM, ACVIM<sup>2</sup>

<sup>1</sup>NorthStar VETS, Robbinsville, NJ

<sup>2</sup>Petcare Oncology, Bannockburn, IL

<sup>3</sup>Western College of Veterinary Medicine, University of Saskatchewan, Saskatoon, SK, Canada

\*Corresponding author: Dr. Ericksen (tericksen@northstarvets.com)

Received February 28, 2023

Accepted June 12, 2023

doi.org/10.2460/javma.23.02.0119

## OBJECTIVE

To evaluate the outcome and effects of single high-dose radiation therapy with the aid of liquid fiducial markers in dogs following resection of soft tissue sarcomas (STSs).

## ANIMALS

36 client-owned dogs.

## METHODS

Dogs with a histologic diagnosis of a grade II or III STS that underwent liquid fiducial guided single fraction, 20-Gy stereotactic radiation therapy following surgical excision of an STS between May 2017 and March 2019 were prospectively enrolled in this study. Data collected from the medical records included patient signalment, tumor-related information, treatment details, and outcome. Kaplan-Meier survival analysis was performed for overall survival time (OST) and disease-free interval (DFI). The median OST and DFI were not reached, so restricted mean OST and DFI were also calculated.

## RESULTS

36 dogs were included in the study. All dogs underwent radiation therapy a mean of 36.1 days (range, 20 to 59 days) after surgery. Acute and delayed radiation toxicity effects occurred in 80.5% and 36.1% of dogs, respectively, all of which affected the skin. Tumor recurrence was noted in 24.3% of dogs with a median time to recurrence of 272 days (range, 14 to 843 days). The restricted mean OST was 1,556 days (range, 1,383 to 1,728 days) and restricted mean DFI was 1,330 days (range, 1,101 to 1,559 days).

## CLINICAL RELEVANCE

The results of this study showed that administering a single 20-Gy fraction of radiation in combination with a liquid fiducial marker to treat marginally or incompletely resected STS in the absence of gross disease resulted in similar OST and DFI compared to other previously reported radiation protocols.

**S**oft tissue sarcomas (STSs) are a heterogeneous group of mesenchymal tumors that represent up to 20% of all skin and subcutaneous tumors in the dog.<sup>1-3</sup> These typically solitary tumors include fibrosarcoma, peripheral nerve sheath tumors, perivascular wall tumors, liposarcoma, myxosarcoma, and undifferentiated sarcomas. They are commonly found in middle- to older-aged dogs, with large breeds being over-represented.<sup>1,2</sup> STSs share common characteristics including slow growth, local invasiveness, and a decreased tendency for metastatic spread. They grow along paths of least resistance and infiltrate surrounding tissues and fascial planes via finger-like

projections, which makes tumor recurrence after surgical resection common; rates range from 15% to 75% based on histologic grade.<sup>1,2</sup> Risk factors for local tumor recurrence include high histologic grade, large tumor size, and incomplete surgical margins.<sup>1,2</sup>

The majority of STSs are found on the distal extremities, making complete surgical resection with the recommended wide surgical margins difficult to achieve.<sup>3,4</sup> To overcome surgical limitations in these areas, eliminate residual microscopic disease, and therefore minimize recurrence, postoperative radiation therapy can be employed once the surgical wound has healed and sutures removed. While there

is no established consensus regarding total dose, full course fractionated protocols with cumulative doses up to 63 Gy have been recommended to better control recurrence following incomplete surgical margins and have been shown to result in a median time to tumor recurrence of 798 days.<sup>2</sup> While the use of conventionally fractionated radiation therapy allows the delivery of higher total doses, which leads to the intended death of neoplastic cells, irradiation of normal tissue leads to more late tissue effects such as tissue fibrosis, necrosis, or loss of function.<sup>2</sup>

To allow for the more precise use of higher doses per fraction, stereotactic radiation therapy (SRT) has been used. SRT minimizes the volume of normal tissue receiving an increased radiation dose, decreases the total number of anesthetic episodes, and is more convenient for owners. SRT requires a precisely defined target to direct the beam of radiation to the appropriate anatomic location, something that has been previously achieved through the use of metal vascular clips or other traditional metal fiducial markers. Recently, a novel liquid fiducial marker (BioXmark; Nanovi A/S) has been described for use in people with breast, esophageal, head and neck, lung, and bladder tumors and also in animals with oral tumors. This liquid fiducial marker is biocompatible and gradually absorbed over approximately 6 months, is positionally stable in the body for up to 3 months, results in minimal artifact on imaging, and allows identification of a consistent target for each radiation treatment.<sup>5,6</sup>

The first objective of this prospective study was to evaluate the outcomes and effects of a single high dose of radiation on dogs following narrow or incomplete excision of grade II and III STSs. The second objective was to evaluate the utility of a liquid fiducial marker in accurately defining a stereotactic radiation treatment location, in the absence of gross disease, in dogs following narrow or incomplete resection of STS. We hypothesized that a single high dose of radiation following narrow or incomplete surgical excision of a grade II or III STS would result in favorable outcomes with minimal complications and tumor recurrence and that a liquid fiducial marker would better define the planned treatment location in the absence of a gross tumor.

## Methods

### Study design and data collection

This was a prospective study. Dogs from 6 PetCure Oncology locations with a histologic diagnosis of a narrowly (< 3 mm)<sup>7</sup> or incompletely excised grade II or III STS were prospectively enrolled into this study. Each dog was treated with a standardized protocol incorporating a single postoperative liquid fiducial guided 20-Gy fraction of SRT over the study period, May 2017 to March 2019. This protocol was developed and approved by the PetCure Oncology scientific advisory board, an independent review board with oversight on all clinical research protocols. Dogs had to have complete medical

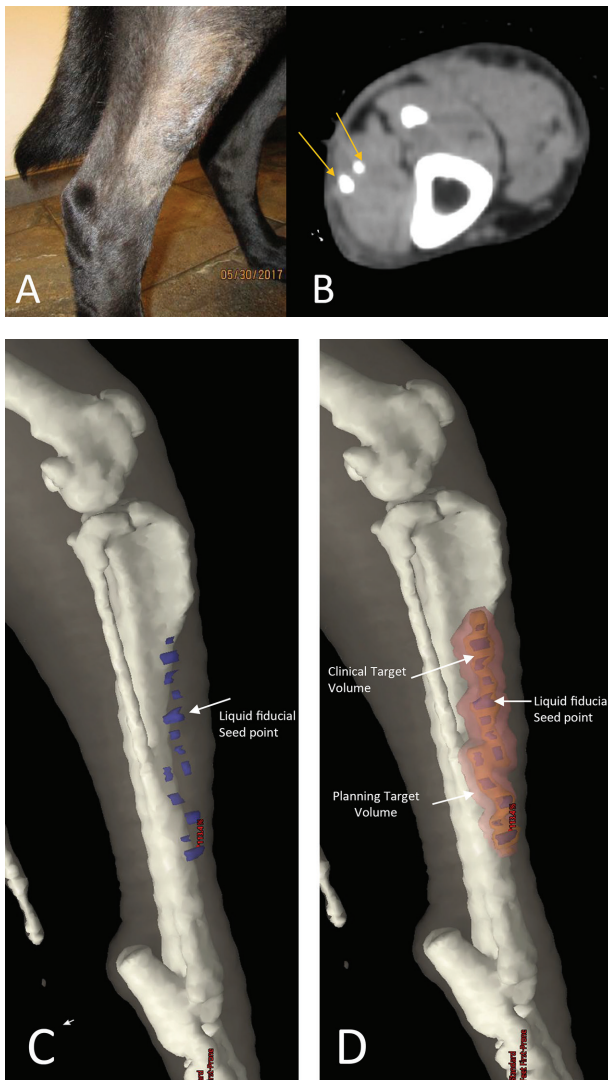
records which included patient signalment (age, breed, sex, and body weight), tumor information (location, histologic type and grade, and previous treatments), radiation treatment plan details, adjuvant treatment, and outcome. Follow-up data collected from the medical records and through communications with referring veterinarians and owners included information pertaining to adverse effects of radiation, response to treatment, tumor recurrence, date of detected tumor recurrence, additional treatments, survival time, and cause of death. Adequate follow-up was defined as information in the medical record pertaining to tumor progression and patient survival time for  $\geq 6$  months unless tumor progression or patient death occurred sooner. Dogs were excluded if their surgical scars were not linear, the scar was due to a reconstructive procedure, there was lateral skin movement of > 0.5 cm, and the biopsy results indicated complete resection of the tumor. Dogs that received postoperative chemotherapy were not excluded from the study.

### Treatment planning and SRT

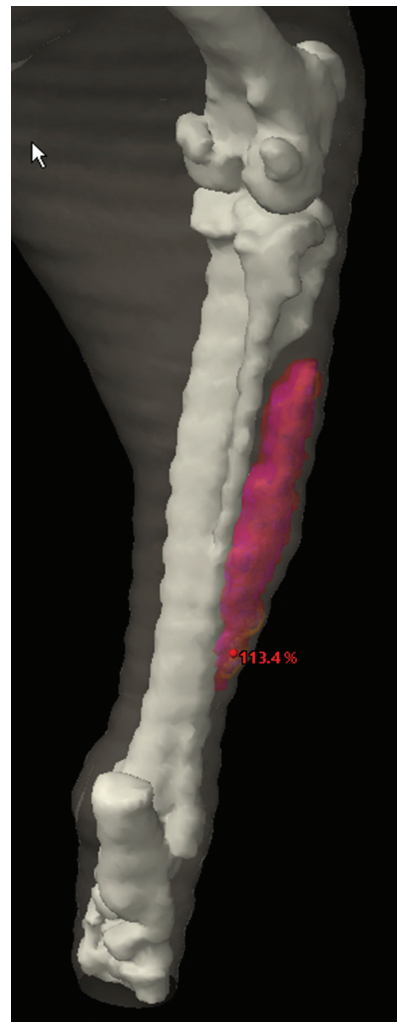
Prior to entry into the study, patients were evaluated to ensure they were appropriate candidates for the fiducial marker administration on the basis of their surgical scar characteristics. To be included, the surgical scar needed to be linear with minimal lateral movement as judged by the attending clinician. Patients with reconstructive scars, skin grafts, or > 0.5 cm lateral or craniocaudal skin movement with respect to the initial surgical scar location were excluded from the study. Additionally, all patients were fully staged for their STSs and underwent standard baseline diagnostic testing including CBC, serum biochemical profile, urinalysis, and either 3-view thoracic radiographs or CT. Animals with significant comorbidities were excluded.

The region of the prior surgery was shaved to allow more accurate delineation of the surgical scar. The liquid fiducial (PetXmark; Nanovi A/S) was drawn up in microdose syringes (Microdose; Vlow Medical BV) to accurately deliver 10  $\mu$ L of the liquid fiducial and injected at 1-cm increments to a maximum depth of 0.5 cm along the scar, including an additional 1 cm at each end; the liquid fiducial marker was administered at the time of initial planning CT scan following surgery. Following injection, 5 to 10 minutes were allowed to pass before the patient was immobilized to prevent excess manipulation of the site before the liquid fiducial marker could solidify. Once this time had passed, a standard clamshell immobilizer was created and a radiation therapy planning CT was performed. The bottom portion of the clamshell consisted of a self-hardening thermoreactive foam (Alpha Cradle; Smithers Medical Products Inc), and the top half was made using a standard thermoplastic mask (Proform thermoplastic; Civco Radiotherapy). All patients in the study had a permanent immobilizer created.

A 3-D plan was generated for each patient using planning software (Varian Eclipse version 15.6; Varian Medical Systems Inc). The fiducial markers were contoured, then an interpolation algorithm was applied to create a roughly tubular structure. This was defined as the clinical tumor volume, and a 0.5- to 1-cm expansion was applied to define the planning target volume (PTV); the appearance of the liquid fiducial marker on CT and 3-D CT reconstruction radiation planning for a clinical patient are shown (**Figures 1 and 2**).



**Figure 1**—A—A clinical patient presenting following incomplete excision of a soft tissue sarcoma on the right lateral crus. B—Two liquid fiducial marker sites can be seen side by side as hyperattenuating spherical opacities (orange arrows) and show minimal scatter artifact. C—A 3-D CT reconstruction of the planned treatment site shows the liquid fiducial marker as seed points (blue), which can then be interpolated to define a clinical tumor volume (CTV) in the absence of gross disease. D—The final treatment plan can be seen where the CTV (orange) overlies the liquid fiducial seed points (blue). The planning target volume (pink) is seen overlying the CTV and allows for the sparing of normal skin receiving excess radiation exposure.



**Figure 2**—A 3-D CT reconstruction treatment plan showing a 95% dose cloud with skin sparing for the dog described in Figure 1.

The amount of PTV expansion was chosen by the planning radiation oncologist on the basis of patient anatomy and the amount of lateral movement that could be exerted on the scar. After the PTV expansion was applied, 3 mm were cropped from the surface in an effort to spare full-thickness skin. Both target volume and organ-at-risk metrics were evaluated in all patients. The target volume metrics were defined as 95% dose to 95% of the PTV, with a gradient measure < 1 cm and a conformity index between 95 and 110. The primary organ at risk of interest was skin, for which the point dose maximum was defined as < 26 Gy and the volumetric constraint was set at < 10 cc at 23 Gy. Either portal dosimetry or a QA plan (MapCHECK; Sun Nuclear Corp) was generated and validated prior to scheduling the patient for treatment.

Patients were anesthetized, immobilized, and their positioning was confirmed using cone beam CT prior to delivering the radiation dose using a linear accelerator (Trilogy, Halcyon, or 21EX [based on hospital location]; Varian Medical Systems Inc). All treatment fields were delivered using volumetric modulated arc therapy techniques in an effort to minimize anesthetic time during treatment. Once the radiation dose was delivered, patients were transferred to recovery and

then discharged when safe to do so. Rechecks were scheduled at 2 weeks and then as needed. All pet owners were provided with clear and specific instructions to prevent or minimize self-trauma in the weeks and months after radiation therapy delivery.

### Histopathology review

H&E-stained sections of each biopsy were submitted for independent histopathological review by a board-certified pathologist (RD), who was blinded to the original diagnosis and grade. Biopsies were confirmed as soft tissue sarcomas and provided a standardized histologic grade using the grading system described by Kuntz et al.<sup>8</sup>

### Outcome

Acute toxicity (AT) and delayed toxicity (DT) effects of SRT were scored on the basis of criteria previously described by LaDue and Klein,<sup>9</sup> and any treatments required to address these effects were recorded. In addition to toxicity effects, any complications that were potentially secondary to the administration of the liquid fiducial marker were noted. Clinical outcomes were defined as alive if dogs were still living at the time the study concluded, lost to follow-up, death due to tumor if the tumor or related treatment led to death or euthanasia, and death not due to tumor if the dogs died or were euthanized for causes unrelated to the tumor or direct treatment of the tumor. Dogs in the death not due to tumor group had their cause of death recorded. Tumor recurrence, time to tumor recurrence from SRT date, and the method of diagnosis used to determine recurrence were recorded along with any additional treatments used to address tumor recurrence.

### Statistical analysis

Kaplan-Meier survival analysis was performed for overall survival time (OST), and disease-free interval (DFI). OST was defined as the number of days from the start of SRT to the day of death, and dogs alive at the end of the study period or lost to follow-up were censored. DFI was defined as the number of days from the start of SRT to the day of documented tumor recurrence, and dogs that were alive at the end of the study period, were lost to follow-up, or died without evidence of tumor recurrence were censored. Following survival curve analysis for OST and DFI, analysis comparing the effect of grade on both parameters was performed using the Gehan-Wilcoxon analysis. The median OST and DFI were not reached, so restricted mean OST and DFI were also calculated. Restricted mean was defined as the area under the survival curve up to the end of final follow-up and can be interpreted as the average survival time or life expectancy during the duration of the study.<sup>10</sup> Statistical analyses were performed using statistical software (NCSS 2022 version 22.0.5; NCSS LLC).

### Results

Seventy-nine biopsies of canine masses were received. Seven biopsies received a diagnosis other than STS (including osteosarcoma, melanoma,

granulation tissue, and ruptured sebaceous and hair follicle tumors). Of the 72 of the cases that were received, 33 were designated as grade I STSs and 1 had complete surgical margins and as such did not meet the inclusion requirements for the study. Thirty were designated as grade II, with 8 designated as grade III soft tissue sarcomas. Two dogs with grade II STSs were excluded from the study, one because of inadequate follow-up and the other because it received conventionally fractionated radiation therapy instead of SRT.

Thirty-six dogs with STS diagnosed on the basis of histopathology following surgical excision and treatment with a single 20-Gy fraction of radiotherapy were included in the study; tumor locations are noted (**Table 1**).

**Table 1**—Soft tissue sarcoma tumor locations.

Location	No. of patients (n = 36)
Antebrachium	6
Carpus	4
Elbow	3
Tarsus	3
Thorax	2
Forepaw	2
Pelvis	2
Shoulder	2
Stifle	2
Thoracic limb—unspecified	2
Axilla	1
Cervical	1
Mammary chain	1
Mandible—gingiva	1
Sciatic nerve	1
Supraspinatus tendon	1
Trunk	1
Zygomatic arch	1

Mitotic count information was available for all dogs. The overall median mitotic count was 10/10 hpf (mean, 15.1/hpf; range, 1 to 87/10 hpf). The median mitotic count for grade II STS was 7.5/10 hpf (mean, 9.32/hpf; range, 1 to 32/10 hpf) and for grade III STS was 21.8/hpf (mean, 37.1/10 hpf; range, 14.5 to 87/10 hpf). The mean age and body weight at the time of treatment was 9.01 years (range, 2 to 15 years) and 25.4 kg (4.77 to 45.3 kg). Of the 36 dogs, 22 (61.1%) were castrated males, 13 (36.1%) were spayed females, and 1 (2.8%) was an intact male. Concurrent diseases noted in the medical records included valvular heart disease (n = 3), hepatopathy (2), hypothyroidism (2), and 1 of each of the following: Cushing disease, diet-responsive diarrhea, inflammatory bowel disease, mast cell tumor, multicentric lymphoma, perianal fistula, thyroid nodule, and soft tissue sarcoma at an unrelated site.

Surgical margins based on histopathology report were available for all dogs and indicated narrow excision in 11 (30.6%) dogs and incomplete excision in 25 (69.4%) dogs. Within the group of dogs with narrow surgical margins, 8 (72.7%) dogs had a grade II STS and 3 (27.3%) dogs had a grade III STS. Within the group of dogs with incomplete surgical margins, 19 (76%) dogs had a grade II STS and 6 (24%) dogs had a grade III STS. All dogs with known incomplete or narrow surgical excision underwent radiation therapy with a mean duration between



surgery and SRT of 36.1 days (range, 20 to 59 days). All dogs were administered the liquid fiducial marker as described and received a single fraction of 20 Gy.

AT effects occurred in 29 of the 36 (80.5%) dogs, all of which affected the skin. Nineteen dogs had a score of 1, 4 dogs had a score of 2, and 6 dogs had a score of 3. AT scores of 1 and 2 did not require any medical intervention. Of the dogs with AT scores of 3, treatment included wound debridement ( $n = 1$ ), antibiotic therapy (2), and no treatment (2) and the medical record did not specify whether additional therapy was provided for 1 dog. DT effects occurred in 13 of the 36 (36.1%) dogs, all of which affected the skin at a median time of 255.5 days (mean, 282.2 days; range, 196 to 524 days). Twelve dogs had a toxicity score of 1, and 1 dog had a score of 3. Dogs with DT scores of 1 did not require any medical intervention. The dog with a score of 3 developed a full-thickness necrotic wound at the treatment site 233 days following radiation therapy and required wound debridement followed by a rotational skin flap to close the defect, which then went on to heal without any additional complications. In addition to adverse radiation effects, 2 dogs had a suspected skin reaction to the liquid fiducial marker based on inflammation at the injection site. One dog was treated with antibiotics and pain medication and the other dog was treated with pain medication alone which led to resolution of signs.

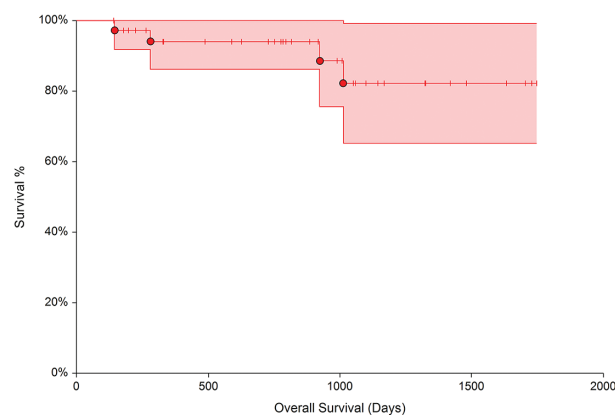
The median follow-up time was 812 days (mean, 770.5 days; range, 141 to 1,599 days). At the end of the study period, 13 dogs were alive, 22 were deceased, and 1 was lost to follow-up. Four dogs were noted to have died as a result of STS, although no formal necropsy was performed in any of these animals. Seventeen dogs died of causes unrelated to STSs, including euthanasia because of poor quality of life due to impaired mobility in 4 dogs, hemoperitoneum secondary to a ruptured splenic mass in 2 dogs (1 hemangiosarcoma and 1 splenic myelolipoma), and 1 each of the following: ruptured unclassified liver mass, disseminated mast cell disease, gastric mast cell tumor, unclassified metastatic adrenal neoplasia, aspiration pneumonia, unclassified metastatic liver neoplasia, lymphoma, severe pancreatitis, and unclassified subcutaneous neoplasia. Additionally, 2 dogs were deceased due to unknown causes and did not undergo necropsy to confirm a cause; these 2 dogs were excluded from statistical analysis.

Tumor recurrence was noted in 9 of 36 (25%) dogs with a median time to recurrence of 272 days (range, 14 to 843 days). Six of 28 (21.4%) dogs with grade II STS had local recurrence, while 3 of 8 (37.5%) dogs with grade III STS had local recurrence. Local recurrence rates did not differ significantly on the basis of tumor grade ( $P = .63$ ). Tumor recurrence was definitively diagnosed on the basis of histopathology ( $n = 3$ ) or cytology (3). Tumor recurrence was suspected on the basis of clinical evaluation but not definitively confirmed in an additional 3 dogs. Of the dogs with tumor recurrence, 1 dog was treated with chlorambucil and piroxicam, 1 dog had a pelvic limb amputation due to tumor recurrence on the left hock, and 1 dog had tumor recurrence on the distomedial aspect of the antebrachium, which was debulked, but this dog was eventually euthanized due to tumor progression and impaired mobility. Five dogs had no treatment pursued

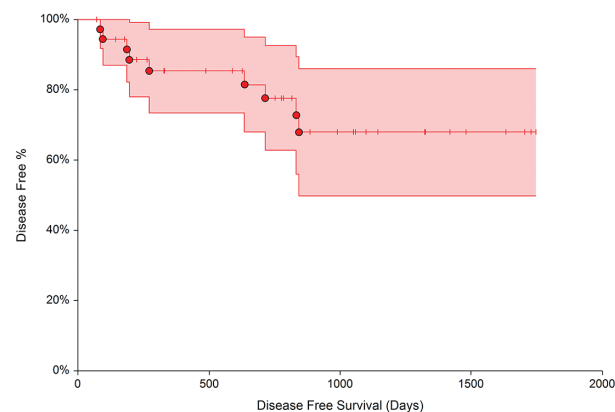
after tumor recurrence. No information regarding additional treatment was reported in 1 dog.

Postoperative chemotherapy was administered to 4 of 36 (11.1%) dogs due to recurrence of the tumor or metastatic disease with 1 dog diagnosed with grade II STS and 3 dogs with grade III STS. The dog with grade II STS received lomustine (Gleostine) at 26 days post-radiation therapy for tumor recurrence. Of the 3 dogs with grade III STS, 1 received metronomic therapy with chlorambucil (Leukeran) and piroxicam (Feldene) at 675 days postradiation for recurrence and the other 2 received doxorubicin (Adriamycin) at 14 and 87 days postradiation due to metastatic disease.

The restricted mean OST was 1,556 days (range, 1,383 to 1,728 days); however, median survival time was not reached (**Figure 3**). There was an 85% likelihood that a dog would survive 1,012 days. The restricted mean DFI was 1,330 days (range, 1,101 to 1,559 days); however, median DFI was not reached (**Figure 4**). There was a 70% likelihood that a dog would have a DFI of 843 days.



**Figure 3**—Kaplan-Meier survival curve for overall survival time for 36 client-owned dogs with STS treated with a single 20-Gy fraction of SRT. The restricted mean overall survival time was 1,556 days (range, 1,383 to 1,728 days); however, median survival time was not reached. Steps on the curve represent the death of  $\geq 1$  dog, tick marks represent dogs that were censored, and the shaded area represents the 95% CI at each time point.



**Figure 4**—Kaplan-Meier survival curve for disease-free interval for the dogs described in Figure 3. The restricted mean disease-free-interval was 1,330 days (range, 1,101 to 1,559 days); however, median survival time was not reached. **See** Figure 3 for the key.

## Discussion

The results of this study show that when using a single high-dose radiation fraction (20 Gy) in combination with a liquid fiducial marker to treat marginally or incompletely resected STSs, there was a mean OST of 1,556 days and mean DFI of 1,330 days with a 70% likelihood of patients reaching 843 days before experiencing local recurrence of the tumor. In addition, while acute and late toxicity effects were seen in 81% and 35.1% of dogs, respectively, they were limited to the skin only and the majority of these effects were minimal and self-limiting or only required medical management. Median values for OST and DFI were not reached; therefore, it is difficult to directly compare the results reported here to previous studies. When compared to studies evaluating the use of SRT,<sup>11</sup> conventionally fractionated radiation therapy (CFRT),<sup>12</sup> and hypofractionated radiation therapy,<sup>7,13,14</sup> median OST was longer compared to each of the 3 previously reported therapies, and DFI was longer than SRT and hypofractionated radiation therapy but similar to that of CFRT. A study by Kung et al<sup>7</sup> in 2016 evaluated the use of hypofractionated radiation therapy and found that grade was a prognostic indicator, with patients diagnosed with grade III STS having a median OST of 940 days. There were 8 dogs in the current study that were diagnosed with grade III STS: 1 was lost to follow-up, 4 were alive at the end of the study period, and 3 died of causes unrelated to their tumor at 141, 727, and 1,167 days after treatment. The mean OST of the 7 dogs that completed the study was 880 days (range, 196 to 1,323 days). It is important to note that 3 of these dogs underwent adjunctive chemotherapy, which may have contributed to a prolonged survival time. These findings are similar to those of Kung et al<sup>7</sup> and suggest that if patients are treated early and with a single large dose of radiation at the appropriate location, even dogs with high-grade STSs can have a long DFI; however, the addition of postradiation chemotherapy may have contributed to our longer survival times rather than radiation therapy alone.

The overall recurrence rate in this population of 36 dogs was 25% (9/36), with a mean time to recurrence of 384 days. When looking at the dogs in our population with incomplete margins specifically, the recurrence rate increased to 36%, which is slightly higher than the recurrence rate found in a recent meta-analysis by Milovancev et al.<sup>15</sup> After reviewing the literature, these authors found that 33.3% of incompletely excised STS recurred and it was strongly suggested that microscopically complete surgical margins significantly reduced risk for local tumor recurrence in canine STSs. While the current study did not specifically evaluate risk factors for tumor recurrence or tumor progression, previous studies have found that an increased mitotic index, higher grade, and increased duration of radiation therapy were risk factors for tumor recurrence.<sup>12,16</sup> While the mean mitotic count for the dogs in this study with grade II STS was 9.39 and 37.1 for grade III STS, 6 of 9 dogs with recurrence were those with grade II tumors.

Reporting of histopathologic findings including margins, grade, and tumor classification has been found to be extremely variable. A study by Livaccari et al<sup>17</sup> found that while histologic margins were described in 91.6% of reports, only 59.6% of those reports used objective measurements to determine margins. That study also found that histological classification of STS was only stated in 50% of reports, which was similar to the current study, in which 64% of reports did not specify the type of STS. In addition, a recent systematic review<sup>18</sup> identified that 56.6% of studies evaluating STS and MCT reported that histologic margins were reported as either complete or incomplete. Margins are an important factor when excising STSs and are important in determining how to proceed with postoperative recommendations including making recommendations for additional surgery, radiation therapy, or chemotherapy. Given the findings of these studies, histologic margins should ideally be reported using standardized, objective measurements rather than subjective or dichotomous reporting.

Dogs in the current study had an 81% and 35.1% occurrence of acute and DT scores, respectively, all limited to the skin. Of the dogs experiencing AT, 80% (24/36 dogs) had AT scores of 1 or 2, which required no treatment. Among those with AT scores of 3, only 1 dog required wound debridement. These findings are similar to previous reports in which a majority of patients undergoing SRT,<sup>11</sup> CFRT,<sup>12</sup> and hypofractionated radiation therapy<sup>14</sup> for STS had self-limiting ATs with AT scores of 1 or 2. Of the dogs with DT in this study, 92.3% (12/13) had a DT score of 1 and required no treatment. One dog had a DT score of 3 and required wound debridement and a rotational skin flap to close the defect. The occurrence of DT reported here was slightly higher compared to a recent study by Crownshaw et al<sup>12</sup> in which 21.9% of patients developed signs of DT following CFRT. These findings along with those of previous studies show that while AT and DT may occur in a large portion of patients after SRT, many of these patients require minimal to no intervention. In the cases of dogs with higher AT or DT scores that require additional surgical intervention such as wound debridement or reconstructive surgeries, it is important to recognize that healing may be compromised due to radiation therapy and this must be considered when formulating a treatment plan.

The traditional clinical approach among veterinary radiation oncologists has been to avoid SRT when gross disease is not present, since there is no clearly definable treatment target. This is in contrast to the treatment of brain metastases in humans for which SRT is used to treat postsurgical resection cavities where microscopic disease is left behind. Two human studies found that when SRT was used to treat microscopic disease within resection cavities, the 12-month local control rates were 79%<sup>19</sup> and 82%.<sup>20</sup> With the addition of a liquid fiducial marker, injection of the marker along the scar line allowed for proper radiation planning by providing a target. Liquid fiducial markers have been used safely and

successfully in people receiving CFRT or SRT for tumors of the bladder,<sup>21</sup> breast,<sup>22</sup> esophagus,<sup>23,24</sup> and lung.<sup>25,26</sup> While its use in animals has been limited at this point, a feasibility study<sup>5</sup> in dogs with oral tumors including fibrous hyperplasia, acanthomatous ameloblastoma, osteosarcoma, and myxosarcoma showed that injection of 10  $\mu$ L of liquid fiducial was easily identified on CT scan and improved gross tumor volume contouring. The liquid fiducial marker used in this study, PetXmark, is a liquid, iodine-based, and nonmetallic formulation with ethanol and sucrose derivatives. This marker offers several benefits including limited imaging artifact when identified on CT or MRI, positional stability over a minimum duration of 3 months, fast and easy application, and the ability to develop a clinical tumor volume for targeting of SRT in the absence of gross disease. This all translates to an easily used and identifiable fiducial marker that will be present throughout the duration of radiation therapy and allows for SRT in the absence of gross disease.

The use of the liquid fiducial marker in the dogs in this study allowed treatment of the affected area with a single high dose of radiation with good local disease control and minimal complication. This is an important finding as it offers an alternative to CFRT for owners who cannot pursue CFRT for logistic or financial reasons. In addition to owner factors, this alternative course of treatment limits the need for general anesthesia to 2 episodes: one to place the liquid fiducial followed by a planning CT scan and another to treat the tumor. This is an important consideration given that most patients undergoing radiation therapy are older and may have comorbidities that would otherwise increase the risk associated with multiple anesthetic episodes.

There were several limitations to the current study. First, the sample size was small. Second, even though the median duration of follow-up in these dogs was 714 days, neither median OST nor DFI was reached. Third, the dogs in this study had an uncertain resection cavity as SRT was targeted to a surgical scar rather than a known tumor cavity. This limitation may have resulted in over- or underestimating the actual location of tumor cells. Finally, animals with reconstructive scars and/or excessive motion associated with their scars were excluded. While this allowed assessment of the utility of liquid fiducial on a known area of resection with little motion, it may have introduced selection bias. Future studies evaluating the use of this liquid fiducial marker intraoperatively to mark the tumor bed at the time of surgery may help minimize the uncertainty regarding the precise location of the tumor cavity and facilitate use in dogs with reconstructive surgery or in high motion areas.

In conclusion, the results of this study show that administering a single 20-Gy fraction of radiation in combination with a liquid fiducial marker to treat marginally or incompletely resected STS in the absence of gross disease resulted in similar OST and DFI compared to other previously reported radiation protocols. This course of treatment minimizes owner cost and the need for a patient to undergo multiple

anesthetic episodes while achieving good local tumor control. Future studies evaluating the use of this liquid fiducial marker at the time of surgery are needed to determine whether it allows better definition of the resection cavity and can facilitate direct treatment of the surgical site.

## Acknowledgments

The authors declare that there were no conflicts of interest or financial disclosures in connection with this manuscript.

An abstract of this study was presented in part at the ACVS Summit: Scientific Abstract Presentation, Portland, Oregon, October 2022.

## References

1. van Nimwegen SA, Kirpensteijn J. Specific disorders of the skin and subcutaneous tissues. In: Tobias KM, Johnston SA, eds. *Veterinary Surgery Small Animal*. Vol 1. 2nd ed. Elsevier; 2018:1519–1524.
2. Liptak JM, Forrest LJ. Soft tissue sarcomas. In: Withrow SJ, Vail DM, Page RL, eds. *Withrow & MacEwen's Small Animal Clinical Oncology*. 5th ed. Saunders; 2012.
3. Villedieu EJ, Petite AF, Godolphin JD, Bacon NJ. Prevalence of pulmonary nodules suggestive of metastasis at presentation in dogs with cutaneous or subcutaneous soft tissue sarcoma. *J Am Vet Med Assoc*. 2021;258(2):179–185. doi:10.2460/javma.258.2.179
4. Milovancev M, Townsend KL, Tuohy JL, et al. Long-term outcomes of dogs undergoing surgical resection of mast cell tumors and soft tissue sarcomas: A prospective 2-year-long study. *Vet Surg*. 2020;49(1):96–105. doi:10.1111/vsu.13225
5. Clerc-Renaud B, Boss MK, Griffin LR, LaRue SM, Leary D. Potential for BioXmark liquid fiducial marker to improve identification of superficial component of canine oral tumors for computer-based radiation therapy planning. *Can Vet J*. 2019;60(10):1072–1080.
6. Brown KH, Ghita M, Schettino G, Prise KM, Butterworth KT. Evaluation of a novel liquid fiducial marker, BioXmark®, for small animal image-guided radiotherapy applications. *Cancers (Basel)*. 2020;12(5):1276. doi:10.3390/cancers12051276
7. Kung MJB, Poirier VJ, Dennis MM, Vail DM, Straw RC. Hypofractionated radiation therapy for the treatment of microscopic canine soft tissue sarcoma. *Vet Comp Oncol*. 2016;14(4):e135–e145. doi:10.1111/vco.12121
8. Kuntz CA, Dernel WS, Powers BE, Devitt C, Straw RC, Withrow SJ. Prognostic factors for surgical treatment of soft-tissue sarcomas in dogs: 75 cases (1986–1996). *J Am Vet Med Assoc*. 1997;211(9):1147–1151.
9. Ladue T, Klein MK; Veterinary Radiation Therapy Oncology Group. Toxicity criteria of the veterinary radiation therapy oncology group. *Vet Radiol Ultrasound*. 2001;42(5):475–476. doi:10.1111/j.1740-8261.2001.tb00973.x
10. Han K, Jung I. Restricted mean survival time for survival analysis: a quick guide for clinical researchers. *Korean J Radiol*. 2022;23(5):495–499. doi:10.3348/kjr.2022.0061
11. Gagnon J, Mayer MN, Belosowsky T, Mauldin GN, Waldner CL. Stereotactic body radiation therapy for treatment of soft tissue sarcomas in 35 dogs. *J Am Vet Med Assoc*. 2020;256(1):102–110. doi:10.2460/javma.256.1.102
12. Crownshaw AH, McEntee MC, Nolan MW, Gieger TL. Evaluation of variables associated with outcomes in 41 dogs with incompletely excised high-grade soft tissue sarcomas treated with definitive-intent radiation therapy with or without chemotherapy. *J Am Vet Med Assoc*. 2020;256(7):783–791. doi:10.2460/javma.256.7.783
13. Lawrence J, Forrest L, Adams W, Vail D, Thamm D. Four-fraction radiation therapy for macroscopic soft

- tissue sarcomas in 16 dogs. *J Am Anim Hosp Assoc*. 2008;44(3):100–108. doi:10.5326/0440100
14. Cancedda S, Marconato L, Meier V, et al. Hypofractionated radiotherapy for macroscopic canine soft tissue sarcoma: a retrospective study of 50 cases treated with a 5 x 6 Gy protocol with or without metronomic chemotherapy. *Vet Radiol Ultrasound*. 2016;57(1):75–83. doi:10.1111/vru.12308
  15. Milovancev M, Tuohy JL, Townsend KL, Irvin VL. Influence of surgical margin completeness on risk of local tumour recurrence in canine cutaneous and subcutaneous soft tissue sarcoma: a systematic review and meta-analysis. *Vet Comp Oncol*. 2019;17(3):354–364. doi:10.1111/vco.12479
  16. McSparran KD. Histologic grade predicts recurrence for marginally excised canine subcutaneous soft tissue sarcomas. *Vet Pathol*. 2009;46(5):928–933. doi:10.1354/vp.08-VP-0277-M-FL
  17. Livaccari AM, Selmic LE, Reagan JK, et al. Evaluation of information presented within soft tissue sarcoma histopathology reports in the United States: 2012–2015. *Vet Comp Oncol*. 2018;16(4):424–430. doi:10.1111/vco.12397
  18. Abrams BE, Putterman AB, Rupple A, Wavreille V, Selmic LE. Variability in tumor margin reporting for soft tissue sarcoma and cutaneous mast cell tumors in dogs: a systematic review. *Vet Surg*. 2021;50(2):259–272. doi:10.1111/vsu.13539
  19. Soltys SG, Adler JR, Lipani JD, et al. Stereotactic radiosurgery of the postoperative resection cavity for brain metastases. *Int J Radiat Oncol Biol Phys*. 2008;70(1):187–193. doi:10.1016/j.ijrobp.2007.06.068
  20. Do L, Pezner R, Radany E, Liu A, Staud C, Badie B. Resection followed by stereotactic radiosurgery to resection cavity for intracranial metastases. *Int J Radiat Oncol Biol Phys*. 2009;73(2):486–491. doi:10.1016/j.ijrobp.2008.04.070
  21. de Ridder M, Gerbrandy LC, de Reijke TM, Hinnen KA, Hulshof MCCM. BioXmark® liquid fiducial markers for image-guided radiotherapy in muscle invasive bladder cancer: a safety and performance trial. *Br J Radiol*. 2020;93(1111):20200241. doi:10.1259/bjr.20200241
  22. Ciernik IF, Greiss AM. Visualization of the tumor cavity after lumpectomy of breast cancer for postoperative radiotherapy. *Clin Transl Radiat Oncol*. 2018;14:47–50. doi:10.1016/j.ctro.2018.11.003
  23. Machiels M, Voncken FEM, Jin P, et al. A novel liquid fiducial marker in esophageal cancer image guided radiation therapy: technical feasibility and visibility on imaging. *Pract Radiat Oncol*. 2019;9(6):e506–e515. doi:10.1016/j.prro.2019.06.018
  24. de Blanck SR, Scherman-Rydhög J, Siemsen M, et al. Feasibility of a novel liquid fiducial marker for use in image guided radiotherapy of oesophageal cancer. *Br J Radiol*. 2018;91(1092):20180236. doi:10.1259/bjr.20180236
  25. de Blanck SR, Rydhög JS, Larsen KR, et al. Long term safety and visibility of a novel liquid fiducial marker for use in image guided radiotherapy of non-small cell lung cancer. *Clin Transl Radiat Oncol*. 2018;13:24–28. doi:10.1016/j.ctro.2018.07.004
  26. Rydhög JS, Mortensen SR, Larsen KR, et al. Liquid fiducial marker performance during radiotherapy of locally advanced non small cell lung cancer. *Radiother Oncol*. 2016;121(1):64–69. doi:10.1016/j.radonc.2016.06.012